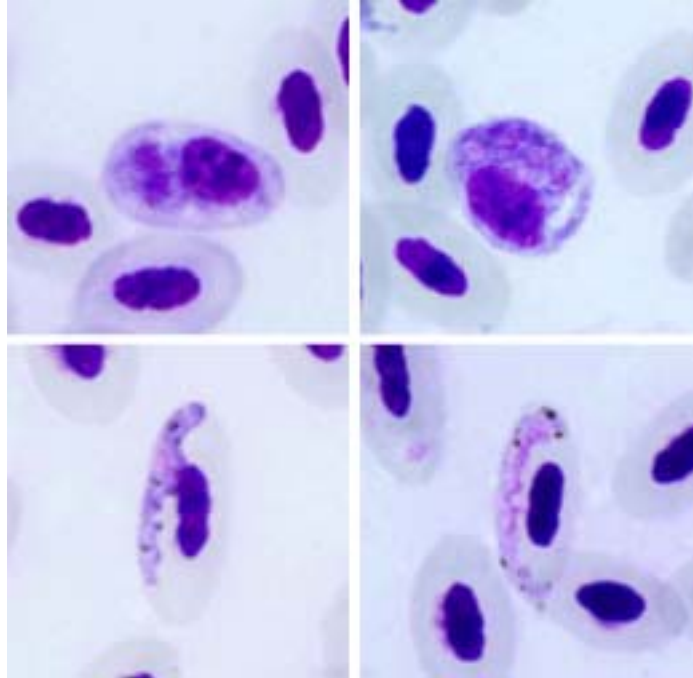


*Plasmodium (Huffia) elongatum* Huff, 1930

**Typical blood stages:**



**Important diagnostic characters of blood stages:**

*Huffia* malaria parasite, which asexual stages develop mainly in young red blood cells, but gametocytes develop mainly in mature red blood cells. Gametocytes are markedly attenuated. Mature erythrocytic merozoites more or less elongated in shape.

**Mitochondrial cytochrome b sequences:**

GRW06

**Avian hosts and distribution:**

Type avian host – *Serinus canaria*.

Additional hosts: numerous species of birds belonging to different orders, particularly common in birds of Passeriformes. Probably cosmopolitan.